

Extended Manual of  
Bone Marrow  
Examination  
(4th edition)



# Extended Manual of Bone Marrow Examination (4th edition)

By

Anwarul Islam

**Cambridge  
Scholars  
Publishing**



Extended Manual of Bone Marrow Examination (4th edition)

By Anwarul Islam

This book first published 2025

Cambridge Scholars Publishing

Lady Stephenson Library, Newcastle upon Tyne, NE6 2PA, UK

British Library Cataloguing in Publication Data

A catalogue record for this book is available from the British Library

Copyright © 2025 by Anwarul Islam

All rights for this book reserved. No part of this book may be reproduced, stored in a retrieval system, or transmitted, in any form or by any means, electronic, mechanical, photocopying, recording or otherwise, without the prior permission of the copyright owner.

ISBN: 978-1-0364-4309-2

ISBN (Ebook): 978-1-0364-4310-8

# *Dedication*

*To my parents, my wife Shelley, sons Dimitri and Pierre*

*To my sister, the late Dr. Afzalun Nessa, Professor of  
Anesthesiology,  
Institute of Post Graduate Medicine and Research in Dhaka,  
Bangladesh  
Who inspired me to become a physician*

*and to my mentors*

*Chester Glomski, M.D  
Professor of Anatomy, State University of New York  
At Buffalo, NY, USA*

*Late Professors Daniel Catovsky, D. A. G. Galton, and John M  
Goldman  
Hammersmith Hospital  
London, England*

*Late Professors Rolf Burkhardt, Munich, Germany, and Bertha  
Frisch, Tel Aviv, Israel*

*Late Professor Edward Henderson, M.D  
Chief of Medicine A  
At Roswell Park Cancer Institute  
Buffalo, New York, USA*



# TABLE OF CONTENTS

|   |     |
|---|-----|
| PREFACE TO THE FIRST EDITION.....   | xi  |
| PREFACE TO THE SECOND EDITION.....  | xii |
| PREFACE TO THE THIRD EDITION .....  | xiv |
| PREFACE TO THE FOURTH EDITION.....  | xv  |
| ACKNOWLEDGEMENTS.....   | xvi |
| CHAPTER 1 .....   | 1   |
| INTRODUCTION  |     |
| CHAPTER 2 .....   | 4   |
| BONE MARROW ASPIRATION  |     |
| CHAPTER 3 .....   | 67  |
| DRY TAP AND THE VALUE OF PREPARING SMEARS FROM THE<br>SMALL AMOUNT OF MARROW LEFT WITHIN THE ASPIRATION<br>NEEDLE |     |
| CHAPTER 4.....  | 76  |
| BONE MARROW TREPHINE (CORE) BIOPSY  |     |
| CHAPTER 5 .....   | 122 |
| SINGLE-USE BONE MARROW BIOPSY NEEDLE  |     |
| CHAPTER 6 .....   | 146 |
| SECOND GENERATION ISLAM SINGLE-USE BONE MARROW<br>BIOPSY NEEDLE   |     |
| CHAPTER 7 .....   | 160 |
| A NEEDLE FOR CLINICAL PATHOLOGISTS TO OBTAIN BONE<br>MARROW CORE SAMPLES DURING AN AUTOPSY                        |     |

|  |     |
|--|-----|
| CHAPTER 8.....   | 166 |
| BONE MARROW SOLID CORE BIOPSY NEEDLE: UTILITY,<br>BENEFITS AND LIMITATIONS OF THE INSTRUMENTS<br>EMPLOYED IN CURRENT DAY HEMATOLOGY AND ONCOLOGY   |     |
| CHAPTER 9.....   | 190 |
| DIAGNOSTIC VALUE OF PROCESSING AND EXAMINATION<br>OF SMALL FRAGMENTS OF MARROW TISSUE LEFT WITHIN<br>THE BIOPSY NEEDLE FOLLOWING AN UNSUCCESSFUL<br>ATTEMPT TO OBTAIN A SOLID CORE BIOPSY SPECIMEN |     |
| CHAPTER 10.....  | 198 |
| BONE MARROW ASPIRATION PRIOR TO BONE MARROW CORE<br>BIOPSY USING THE SAME BONE MARROW BIOPSY NEEDLE:<br>A GOOD OR BAD PRACTICE   |     |
| CHAPTER 11.....  | 208 |
| TIPS FOR SUCCESSFUL BONE ARROW ASPIRATION<br>AND BIOPSY PROCEDURE BY PALPATION METHOD<br>(BLIND ASPIRATION AND BIOPSY)   |     |
| CHAPTER 12.....  | 214 |
| ULTRASOUND GUIDED BONE MARROW ASPIRATION<br>AND TREPHINE (CORE) BIOPSY   |     |
| CHAPTER 13.....  | 227 |
| COMPUTED TOMOGRAPHY (CT) GUIDED BONE MARROW<br>ASPIRATION AND TREPHINE (CORE) BIOPSY   |     |
| CHAPTER 14.....  | 235 |
| THE USE OF THE SMARTPHONE AS A TOOL FOR PRECISELY<br>LOCATING POSTERIOR ILIAC CREST AND TO OBTAIN<br>ADEQUATE SAMPLES OF BONE MARROW ASPIRATION<br>AND TREPHINE (CORE) BIOPSY                      |     |
| CHAPTER 15.....  | 245 |
| BONE MARROW ASPIRATION AND TREPHINE (CORE) BIOPSY<br>BY INTERVENTIONAL RADIOLOGIST   |     |



|   |     |
|---|-----|
| CHAPTER 16.....   | 257 |
| INTRAVENOUS CONSCIOUS SEDATION WITH LOCAL<br>ANESTHESIA OR LOCAL ANESTHESIA ALONE IN<br>PERFORMING A BONE MARROW ASPIRATION<br>AND A TREPHINE (CORE) BIOPSY |     |
| CHAPTER 17.....   | 261 |
| BONE MARROW HARVESTING (STEM CELL COLLECTION<br>FOR TRANSPLANTATION)  |     |
| CHAPTER 18.....   | 264 |
| TECHNICAL CONSIDERATIONS  |     |
| CHAPTER 19.....   | 282 |
| REPORTING AND INTERPRETATION OF BIOPSY SPECIMENS  |     |
| CHAPTER 20.....   | 287 |
| MYELODYSPLASTIC SYNDROMES: DIAGNOSTIC PITFALL<br>AND THERAPEUTIC OPTIONS  |     |
| CHAPTER 21.....   | 304 |
| EXAMPLES OF DESCRIPTIONS OF BONE MARROW BIOPSY<br>(BMB) SECTIONS FROM NORMAL AND REPRESENTATIVE<br>HAEMATOLOGIC AND NON-HEMATOLOGIC DISEASES                |     |
| CHAPTER 22.....   | 353 |
| COMMON PROBLEMS AND THEIR RESOLUTION  |     |
| CHAPTER 23.....   | 356 |
| INFORMATION OBTAINABLE FROM A WELL FIXED, WELL<br>PROCESSED, WELL STAINED, LONG AND UNCRUSHED<br>BONE MARROW BIOPSY SAMPLE                                  |     |
| CHAPTER 24.....   | 362 |
| CLINICAL IMAGES   |     |
| CHAPTER 25.....   | 380 |
| NEW DEVELOPMENTS  |     |

|  |     |
|--|-----|
| CHAPTER 26.....  | 397 |
| BONE MARROW TREPHINE (CORE) BIOPSY USING<br>AN ELECTRIC OR BATTERY OPERATED DRILL  |     |
| CHAPTER 27.....  | 401 |
| INTRAMARROW INJECTION NEEDLE: A NEW TECHNIQUE<br>TO TREAT PATIENTS WITH HEMATOLOGIC AND NON-<br>HEMATOLOGIC MALIGNANCIES BY DIRECTLY INJECTING<br>THERAPEUTIC AGENTS INTO THE BONE MARROW CAVITY |     |
| CHAPTER 28.....  | 412 |
| INJECTION OF CHEMOTHERAPEUTIC AGENTS DIRECTLY<br>INTO THE BONE MARROWCAVITY FOR TREATING PATIENTS<br>WITH HEMATOLOGIC MALIGNANCIES: POSSIBILITIES<br>AND THERAPEUTIC IMPLICATIONS                |     |
| CHAPTER 29.....  | 419 |
| FUTURE DIRECTIONS  |     |
| APPENDIX: PATIENT INFORMATION.....   | 423 |
| SELECTED READING .....   | 428 |
| INDEX.....   | 434 |

## PREFACE TO THE FIRST EDITION

The purpose of this manual is to present a systematic approach to the methods of procurement and examination of bone marrow (aspiration and trephine biopsy) samples which play a crucial role in the diagnosis and management of hematological as well as non-hematological conditions. The manual is designed for medical students, house officers, physicians and other health professionals with an interest in hematology and oncology. It can also be used as a readily available, contemporary reference source for technologists and nurses who are involved in assisting in bone marrow aspiration, biopsy procurement and processing of marrow for cytological, immunological and histological examination. Although most practicing hematologists are familiar with bone marrow sampling techniques for diagnostic evaluation there is a growing body of information that merits review, critical analysis and consolidation in one working reference.

The manual is organized into two major sections. The first is directed towards an appreciation of the advantages, disadvantages and limitations of bone marrow aspiration biopsies specimens. The selection of biopsy site(s) and the diagnostic value of the derived Romanowsky stained dry film smears are discussed. The second section of the text addresses the trephine or solid core bone marrow biopsy specimens. Particular attention is directed to the new and improved instrumentation that has been introduced into the field. In addition to comparing the trephine/core biopsy with the aspiration biopsy technique the particular advantages of the former procedure are evaluated in detail. Finally, considerable attention has been given to the stepwise bedside technique of obtaining ideal bone marrow aspiration and trephine/core biopsy specimens and their processing.

It is recognized that bone marrow aspiration and trephine/core biopsy are specialized clinical procedures. It is associated with well recognized requirements as well as potential problems and pitfalls that are less well known. These considerations and their resolution from a clinical hematologist's viewpoint are specifically included in this text.

## PREFACE TO THE SECOND EDITION

On a vacation in 1943, Edwin Land snapped a photo of his three-year-old daughter, Jennifer, who asked why she could not see the picture *right* now. Land wondered the same thing. He later recalled that by the end of that same day he had pretty much figured out the solution—"except for those details that took from 1943 to 1972."

Land's created "Polaroid" Readers Digest

Readers Digest

Almost fifteen years have passed since the first edition of this book was published. During this time there has been considerable improvement in the technique of procuring bone marrow, particularly the core biopsy sample and its processing into plastic—methyl or glycol methacrylate. The loss of bone marrow core samples during its extraction, in other words, failure to retain the complete biopsy sample within the lumen of the needle after the needle is withdrawn from the patient's body has been a serious continuing problem. Although the importance and significance of this particular problem, i.e. the loss of biopsy sample during the process of its extraction was recognised many years ago and was successfully addressed by a new Islam bone marrow biopsy needle with the 'core retention device'. But until now, this needle had not been available in a disposable form because of the complicated nature and high cost involved with the production of such a needle. In recent years, new technology has emerged by which such needles can be made economically and in large numbers. Taking advantage of this new technology, a new Islam single-use bone marrow biopsy needle that retains the original principle of core retention device has now been produced which has been detailed in this book.

Although the problem of core loss by the conventional bone marrow biopsy needles is now universally recognized and to overcome this problem several different single-use needles have recently been introduced. Each of these needles features different methods of securing a core sample during withdrawal of the needle from the patient's body. Unfortunately, in the process of doing this, all of these needles significantly complicate the procedure by introducing multiple steps and a nearly unmanageable

assortment of extra parts and components. In some cases, these needles contain up to six or more additional parts. Furthermore, these core-capturing devices as they grasp the biopsy specimen may also cause a crush artefact and reduce the amount and quality of marrow tissue available for histological examination.

The advantage of the new Islam single use bone marrow biopsy needle lies in its simplicity and also in the reduced number of parts and steps required to complete the procedure. This new needle essentially contains only three parts—the needle, spacer guide and the stylette. In this new system, the same stylette is used as a pusher to extrude the biopsy sample out of the needle. In addition, the distal cutting end of the needle, which bears the *internal* core retention device, has been fitted with multiple small outside serration's/flutes which enhance the force of boring through the hard cortical bone and facilitate the entry of the main wider portion of the hollow needle into the marrow cavity. Although it now sounds very simple, it took over 30 years to develop the Islam single use bone marrow biopsy needle. In that respect the same analogy (quoted above) that applied to Land is also applicable to Islam.

In general bone marrow aspiration and bone marrow core biopsies are now routinely obtained for the investigation, diagnosis and management of various haematological, non-haematological and various other diseases. The procedure usually involves aspiration of a fluid suspension of bone marrow from the sternum, or from the posterior iliac crests using a sternal puncture or similar needles. The bone marrow core biopsies are usually obtained from the posterior iliac crest with a bone marrow biopsy needle. Since the aspirate and core biopsy provide complimentary and useful information, both specimens are routinely obtained at the same time and usually from the same site in a large majority of cases. Posterior iliac crest is most commonly the site of choice. However, because of the extra time required and the inconvenience of using two needles—one for aspiration and one for core biopsy, and the additional cost involved in using the two needles, some investigators use a single bone marrow biopsy needle for both purposes. The technique of aspiration and obtaining a core biopsy at the same time using the same needle and at the same site has inherent technical problems and other disadvantages which has been highlighted in Chapter 5 and proper method of doing so but without sacrificing the quality of the specimens have been recommended. In addition the book has now been produced in colour and several coloured illustrations of mostly plastic embedded bone marrow biopsy sections in normal and diseased condition have been added.

## PREFACE TO THE THIRD EDITION

In preparing this third edition I have made corrections to a number of minor errors and have improved the text and exposition. This edition has left intact the material of most chapters and added several new chapters including the one on myelodysplastic syndromes depicting the author's perspective and introducing a considerable amount of detailed information concerning the future directions of bone marrow techniques and analysis.

I have tried to emphasize the value of the procedure of obtaining a bone marrow aspiration with an aspiration needle *first*, followed by deriving a trephine (core) biopsy specimen using a separate bone marrow trephine (core) biopsy needle. I have also tried to impart the importance of making fresh, bedside smears from the *first pull* (0.5 ml) of marrow rather than makings them from a diluted marrow sample (the aspirated large amount of marrow obtained in one single pull) which could remain standing at length (even hours) before the marrow suspension is transported to the laboratory. In addition, I have discussed the pros and cons of currently available bone marrow trephine (core) biopsy needles that require extra steps and additional parts (such as core-capturing/core trapping devices) to capture a biopsy specimen such as the Jamshidi, Ranfac and OnControl needles and compared them with the *Islam* bone marrow trephine (core) biopsy needle that has an smooth internal core retention device that avoids the need for any extra components or parts and any additional steps or maneuvers (which may elicit additional pain) to capture the biopsy specimens. Unlike the Islam needle system, the other core-capturing/trapping devices are hard to push over the biopsy specimens and not only cause fragmentation of the biopsy specimens but also inflict considerable damage to the biopsied tissue, particularly to the edge of biopsy specimens.

Finally I wish to add that if any reader of this text, particularly my colleagues in hematology/oncology, interventional radiology and pathology can enhance their knowledge and skill in procuring, processing, analyzing and reporting bone marrow I would consider the effort and journey of writing this text worthwhile.

## PREFACE TO THE FOURTH EDITION

It seems just the other day the third edition of this book was published. Five years have elapsed since its publication. Major changes have taken place in hematology particularly new treatment modalities and immunotherapy. However, there are important upcoming progress signs such as a new instrument for obtaining bone marrow aspiration and bone marrow biopsy using the same needle and without sacrificing the quality of the specimen. This is highlighted in a later chapter in this book. In addition, new chapters encompassing various areas of hematology have been added. Clinical images are included that could be useful to the reader(s).

The ability to confidently interpret the smears of peripheral blood and bone marrow aspirate is an essential skill for hematologists and oncologists. This facet of clinical hematology practice appears to be getting lost as simulation training exercises and digital formats are becoming routine and gaining popularity. This may hinder the interpretation, diagnosis and actual treatment of patients with hematological and oncological disorders. The value of adequate training and learning skills to be able to read and accurately interpret the morphology of peripheral blood and bone marrow aspirate smears has been emphasized.

## ACKNOWLEDGEMENTS

I would like to express my gratitude to Professor Chester Glomski for his enthusiasm and assistance in writing this book. I am also grateful to Mrs. Janet O'Bryan of Cardinal Health for her exceptional personal interest in the development of core retention bone marrow instruments. Additionally, I would like to thank Mrs. Sarah Rettig and Mr. Dirk Schelecht (Moeller Medical, Germany) for their valuable contributions to the design and production of the bone marrow needles.

Sincere thanks are extended to Mrs. Alison Duffy, Commissioning Editor, and Amanda Millar from Cambridge Scholars Publishing in Newcastle upon Tyne, UK, for their professional efforts. I appreciate Neil Halstead for his excellent artwork and Samuel Destefano for his technical assistance. I am thankful to my patients and technicians, who imparted clinical relevance to the text.

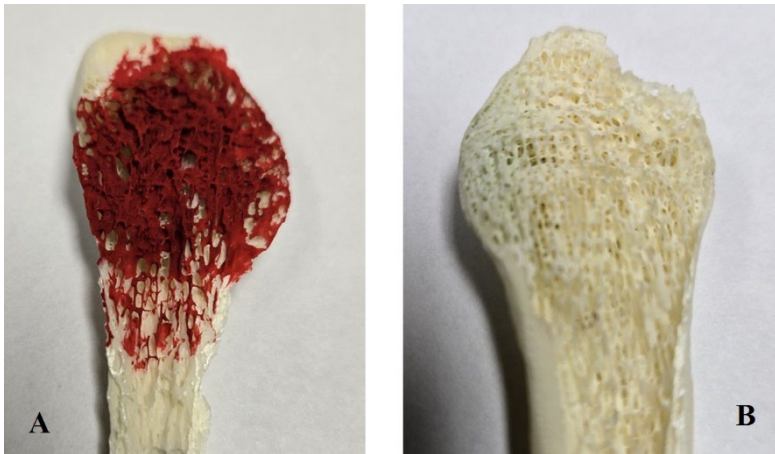I am particularly indebted to Dr. Pierre Islam, my son, for his support with the layout and editorial presentation. Lastly, I would not have been able to accomplish this volume without the unwavering support of my wife, Shelley.



# CHAPTER 1

## INTRODUCTION

### Introduction to bone marrow and its examination



**Figure 1.1.** Representation of human bone marrow (end of a fibula) to show spongy trabecular bone that contains hematopoietic (red) marrow and fat cells (about 50/50 in normal adults). (A) marrow depicting red color, and (B) marrow removed illustrating spongy trabecular bone which is normally filled with marrow (hematopoietic, stromal, fat cells, and vascular structures).

Bone marrow is housed within the inner fixed confines of bone (Figure 1.1 and is the hematopoietic organ responsible for the production of the blood cellular elements that perform vital functions of oxygen transport, protection against bacterial and viral pathogens, control of inflammatory responses, and participation in endothelial repair, bony remodeling as well as clot formation. The importance of bone marrow examination in any hematological disorder cannot be overemphasized. In its absence the investigation of any hematopoietic disorder, unless otherwise well defined, documented and prognostically evaluated, is incomplete. Even in many

cases where the diagnosis is clinically and pathologically established an examination of the bone marrow remains an integral part of the practice of effective, scientific, hematologic medicine.

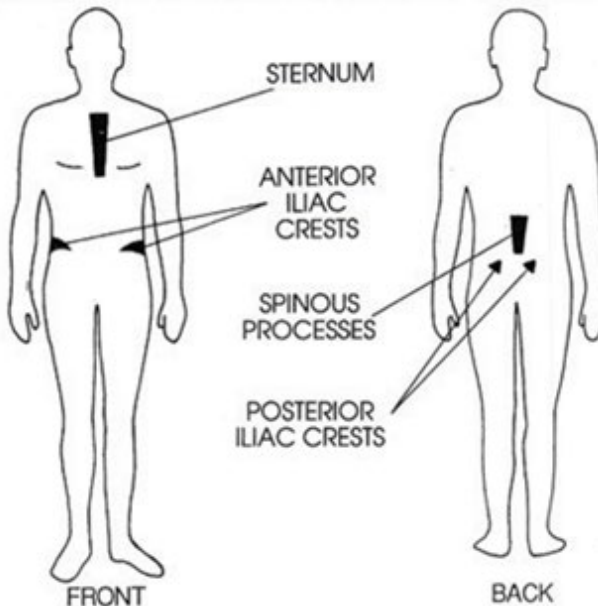
## **Cytologic and histologic analysis**

There are two methods available for diagnostic access to the bone marrow, cytologic and histologic. In the former approach, i.e. bone marrow aspiration, a sample of marrow is withdrawn from a bone via an aspirating needle and a syringe delivering a mixture of free hematopoietic cells, small aggregates or clusters of marrow cells and fat (often termed bone marrow particles, fragments or units), and a variable amount of sinusoidal blood. This material is utilized to prepare dry film smears which are typically stained with a Romanowsky type dye (Leishman, Giemsa etc.). Conversely in the histologic analysis of bone marrow, a biopsy is obtained which provides an undisturbed segment of marrow tissue with its cellular, vascular and osseous *in situ* relationships intact. This tissue is then fixed in a suitable fixative and prepared for paraffin or plastic embedding, sectioning, staining, and subsequent analysis.

## **Access to bone marrow**

### **Marrow Aspiration and Biopsy Sites**

Various sites are available for the access of hematopoietic bone marrow in humans. Satisfactory samples can be routinely aspirated from the sternum, the iliac crest(s) in the region of the anterior or posterior iliac spines and the spinous processes of the lumbar vertebrae (Figure 1.2). A bone marrow aspirate sample can also be obtained from ribs, vertebral bodies or any other bones which show radiologic or other evidence of osseous lesion. The region of the tibial proximal epiphysis is an excellent safe site for sampling bone marrow in children but is not appropriate for adults because of the replacement of its red marrow with adipose cells (inactive yellow marrow). Sternal puncture has historically been the most commonly used technique of aspirating bone marrow. In recent years, however, due to the availability of improved, more durable bone marrow aspiration instruments the region of the posterior iliac spine has become more frequently the site of choice. Bone marrow histologic (solid tissue) biopsies, often termed needle or core biopsies, are usually performed at the anterior or posterior iliac crests. Again, as a result of technological improvements as well as ease of access the posterior locus is becoming more frequently utilized.



**Figure 1.2** Access to bone marrow

### **Quantitative requirements for aspiration and sectioned tissue sampling**

For routine bone marrow cytology the amount of marrow required to be aspirated is minimal. Usually 0.3-0.5 ml is sufficient to prepare several dry film smears. Small volumes are also cited as advantageous because this prevents a dilution of the hematopoietic cells with circulating blood and its cellular contents. Larger volumes may be necessary when cytogenetic and and/or fluorescent flow cytometric analyses are required. For solid tissue (core/trephine) biopsies a 15-20 millimeter-long core of marrow tissue should be obtained to insure the retrieval of adequate, histologically representative, undisturbed specimens. Sections of variable, limited usefulness are also sometimes obtainable by collecting excess bone marrow units from an aspirate, allowing them to aggregate in a plasma/thromboplastin clot and submitting this mass to the embedding and sectioning process.

## CHAPTER 2

# BONE MARROW ASPIRATION

### Sternal Puncture

#### *Introduction*

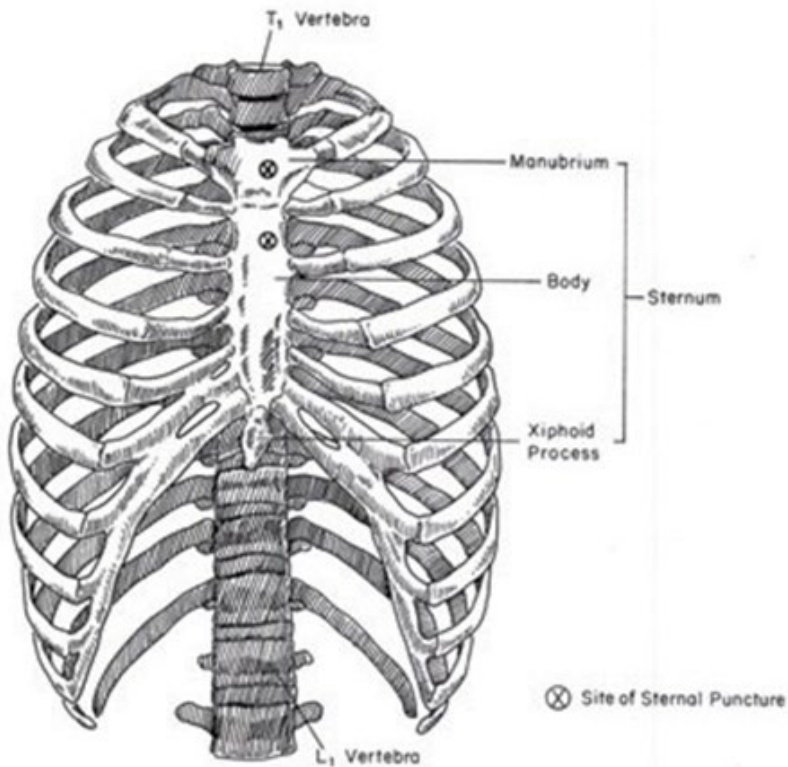
In 1929, Mikhail Innokent'evich Arinkin (figure 2.1) a Russian physician first introduced the technique of bone marrow aspiration from the sternum when he used a lumbar puncture (spinal tap) needle to obtain a marrow aspirate from this site. Since then sternal puncture has become one of the most common intraosseous diagnostic procedures used in the field of hematology. Although the structure in adult humans which yields the largest quantity of bone marrow is the posterior ilium, the sternum has remained one of the most commonly used sites for obtaining aspirates for hematological diagnosis. This preferential selection may be due to the fact that this locus of hematopoietic marrow is near the surface of the body and is easily accessible.



**Figure 2.1** Profile of Mikhail Arinkin (Courtesy of Kilinicheskaja Meditsina).

### *Site*

Sternal puncture is normally performed in the upper part of the body of the sternum, below the sternal angle of Louis and opposite the second intercostal space, midway between the midsternal line and the right or left sternal border (figure 2.2). This particular site is chosen because the needle enters one of the previous centers of ossification where the red marrow is usually more abundant than in the midsternal line. The sternum is most stable at this level and least likely to move or fracture under applied pressure. This area is also separated from the underlying great vessels by a distance of 2-3 cm, while at the levels of third and fourth intercostal spaces, the sternum lies in close proximity to the pericardium and heart.

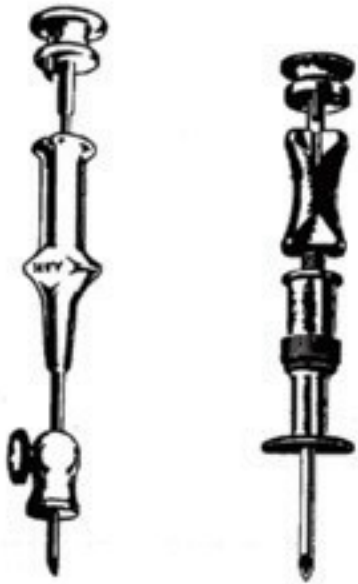

**Figure 2.2** Anterior view of the thorax showing anatomical sites of sternal puncture.

The manubrium of the sternum can also be used as a site for obtaining bone marrow aspirates and is perhaps the safest area of this bone to puncture. But as a rule, particularly in elderly subjects, the manubrium contains more adipose cells than the sternal body and as a result an aspiration at this site may yield an inadequate or non-representative marrow sample. However, completely satisfactory samples are obtained more often than not from the manubrium. If the manubrium is selected for aspiration, the appropriate site for the puncture is about 1 cm above the sterno-manubrial angle and slightly lateral to the mid-line.

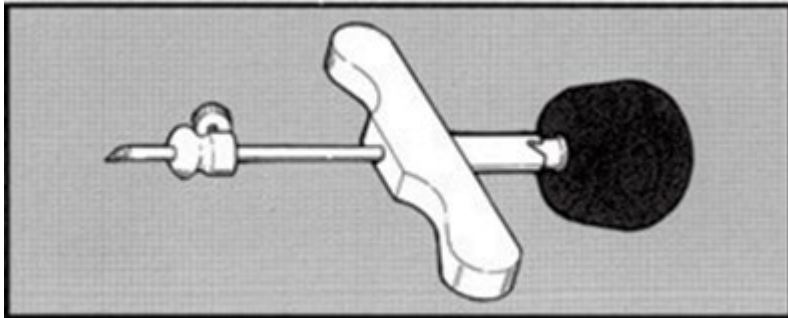
### *Instrumentation*

The needles most commonly used for obtaining bone marrow aspirate samples from the sternum are the Salah and Klima needles (figure 2.3) or their modifications.

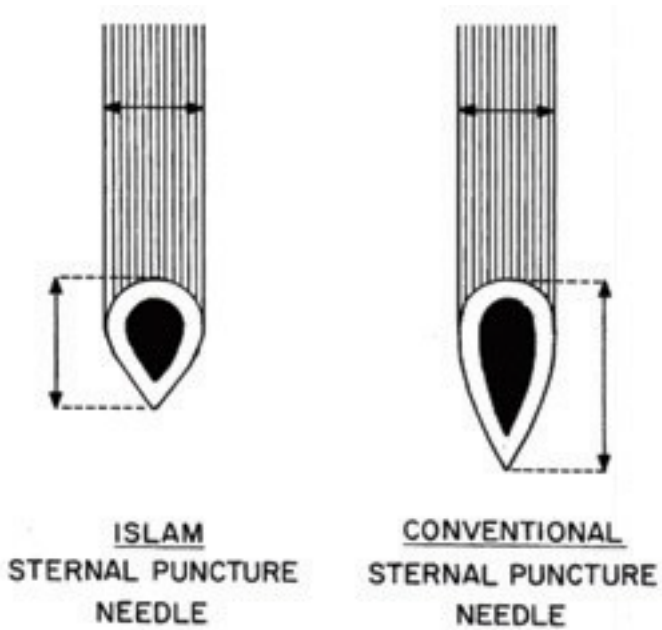


**Figure 2.3** Salah (left) and Klima (right) sternal marrow-puncture needle. (Reproduced from Disorders of the Blood by Whitby and Britton (1957), Churchill, London.)

They were designed in the 1930's and except for the introduction of various kinds of stops and guards there has been very little change over the years in their basic construction and design. These instruments are small, do not conveniently fit the operator's hand, and the lack of a T-bar handle in most instances often makes them difficult to maneuver during the sternal puncture procedure. The recently introduced Islam sternal puncture needle (figure 2.4) overcomes these disadvantages. The domed handle of its stylette rests comfortably in the operator's hand while the T-bar handle provides a firm grip and precise control of the needle movement. An important feature of the Islam sternal puncture needle is the short length of the penetrating segment which is almost half the length of a conventional sternal puncture needle (figure 2.5).




**Figure 2.4** The Islam sternal puncture needle.

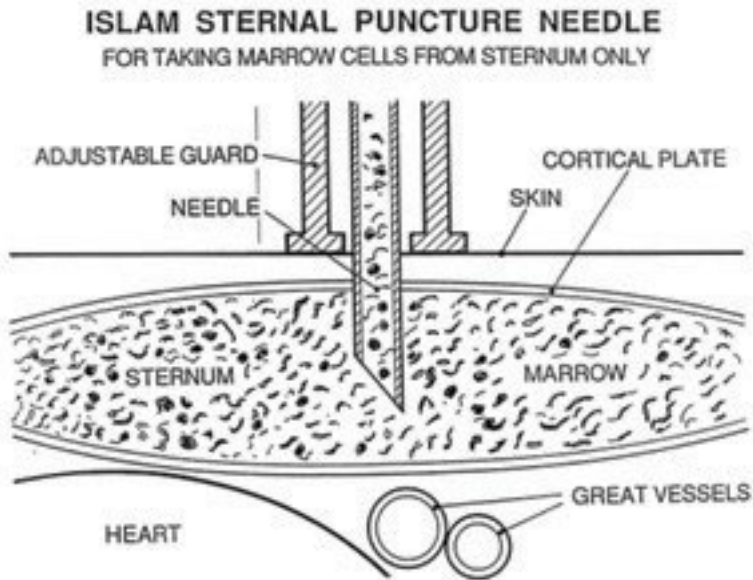


**Figure 2.5a** Schematic representation of the penetrating segment of the Islam (left) and conventional (right) sternal puncture needle. (See text for details)





**Figure 2.5b** Actual picture of the penetrating segment of the conventional (left) and Islam (right) sternal puncture needle.



**Figure 2.6** Schematic representation of the Islam Sternal puncture procedure with respect to the posterior wall of the sternum and the great blood vessels that lie underneath.

This reduces the possibility of accidental penetration of the inner cortex (posterior wall) of the sternum and injuring the great blood vessels that lie underneath (Figure 2.6). Further it also has an adjustable guard to prevent accidental over penetration and a sloped stop at its expanded proximal end for easy fitting and withdrawal of the stilette.

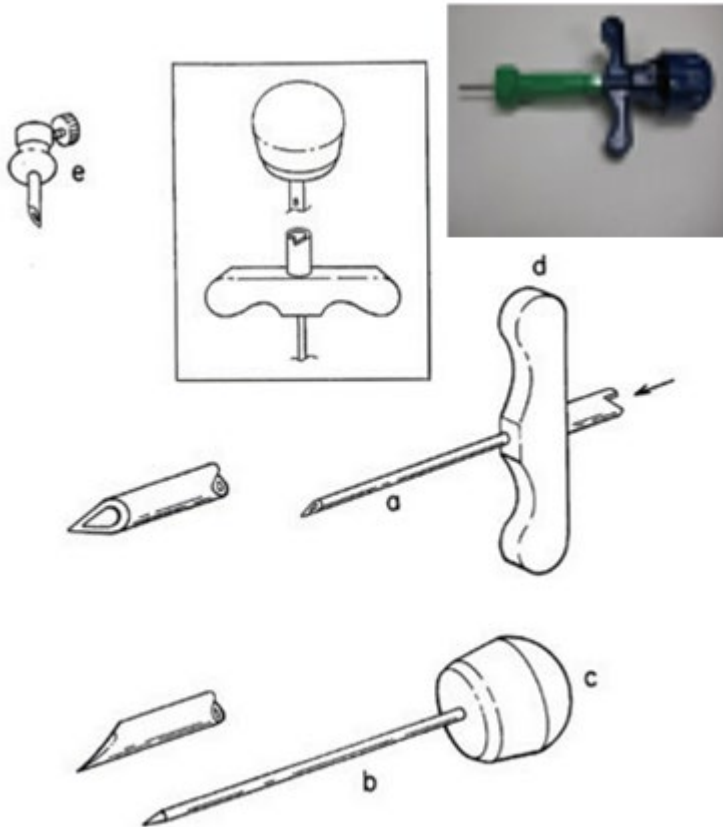
### ***The Islam Sternal Puncture Needle***

#### ***The instrument***

The instrument<sup>1</sup> (figure 2.7) consists of three parts. The standard size *needle* has an overall length of 45 mm, a uniform external diameter of 2.0 mm and a constant internal diameter of 1.25 mm except for the 2-3 mm distal portion where it is beveled to produce a tip (cutting edge) very similar to hypodermic needles but much shorter in configuration. The proximal end of the needle has been fitted with a large *metal bar*

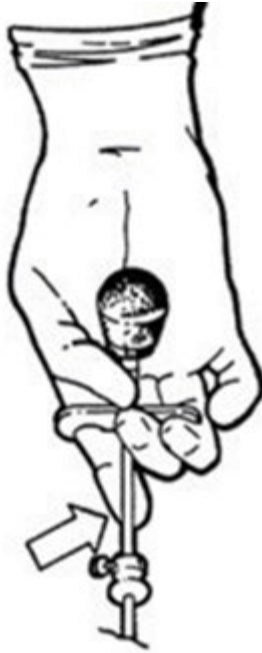<sup>1</sup> The instrument is available in several different sizes (bore diameters) and lengths.

specifically shaped to insure a firm grip and a standard female luer-lock to receive the nozzle of a syringe and to fit the male luer-lock of the stilette.



**Figure 2.7.** Needle [a], stilette [b], dome handle [c], the T-bar handle [d], and the guard [e]. The upper center inset shows the details of the luer-lock attachment of the needle and the handle. The sloped stop at the proximal end of the needle is shown by an arrow. The upper right inset shows a Islam single use sternal/iliac puncture needle.

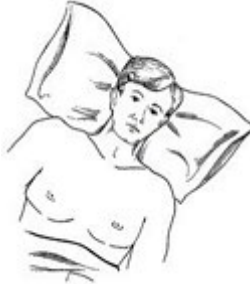The female luer-lock of the needle also has a sloped stop for easy positioning and resting of the metal stud attached to the male luer-lock of the *stilette*. This arrangement makes it possible to automatically position the cutting edge of the *stilette* and needle in the same plane. This design also facilitates the easy unlocking and withdrawal of the *stilette* (by gentle anti-clockwise rotary motion) during the sternal puncture procedure. As has been mentioned the tip of the needle has been specially designed to make it short (figure 2.5 a&b) considering the narrowness of the space between the inner and outer plates of the sternum but sharp enough to easily penetrate the overlying soft tissue and bony cortex. The overall length (from the tip to the base, figure 2.5a) of the penetrating portion of the needle is approximately one half of a conventional needle, thus reducing the fear of accidental penetration of the inner plate of the sternum and injuring the pericardium or heart. The *stilette* is a solid shaft of 1.24 mm in diameter except for the distal portion where it ends in a 2-3 mm beveled tip to fit the beveled tip of the needle to provide means of easy penetration of the soft tissue and bony cortex. The proximal end of the *stilette* has been fitted with a male luer-lock mounted on the inner side of the dome handle to fit the female luer-lock of the needle. It also has a metal stud which fits the sloped stop at the proximal end of the needle and help automatically align the penetrating end of the *stilette* and needle in the same plane. The proximal end of the *stilette* is capped with a *smooth dome-shaped solid nylon handle* 25 mm in diameter and 15 mm deep with 5 mm lightly milled edge. It rests snugly in the operator's hand and the two together (the dome and the T-bar handle) provides a uniquely designed instrument to carry out the sternal puncture procedure with efficiency. The metal *guard* is adjustable and can be fixed at any point over the needle by tightening the screw. The adjustable guard is provided mainly to control the depth of penetration during the sternal puncture and also as a precaution and protection against accidents. In obese patients it may be necessary to adjust the guard to a higher level before attempting to enter the sternum. In such circumstances the positioning of the index finger over the shaft (Figure 2.8) of the needle helps stabilize the needle and permits adequate control during the sternal puncture procedure. If the sternal puncture needle is used for bone marrow aspiration from sites other than the sternum the adjustable guard may be removed before attempting to penetrate the bone and aspirating the marrow.



**Figure 2.8** Demonstrates the actual holding of the Islam sternal puncture needle. The arrow shows the position of the index finger over the shaft of the needle which helps stabilize the needle and permits adequate control of the needle during the aspiration procedure.

**Procedure:**

1. Position of the patient: Place the patient on his/her back with the head and neck comfortably resting on a soft low-lying pillow. In men it may be necessary to shave the skin over the sternum prior to puncture.



2. Site: In adult the sternal puncture is usually performed in the proximal region of the body of the sternum, at the level of the second intercostal space, half way between the midsternal line and the left or right sternal border.

