

# The Basics of Intra-Operative Neurophysiological Monitoring for the Clinician



# The Basics of Intra-Operative Neurophysiological Monitoring for the Clinician:

*A Practical Guide*

Edited by

Chulananda Goonasekera  
and Emma-Jane Smith

**Cambridge  
Scholars  
Publishing**



The Basics of Intra-Operative Neurophysiological Monitoring  
for the Clinician: A Practical Guide

Edited by Chulananda Goonasekera and Emma-Jane Smith

This book first published 2021

Cambridge Scholars Publishing

Lady Stephenson Library, Newcastle upon Tyne, NE6 2PA, UK

British Library Cataloguing in Publication Data

A catalogue record for this book is available from the British Library

Copyright © 2021 by Chulananda Goonasekera, Emma-Jane Smith  
and contributors

All rights for this book reserved. No part of this book may be reproduced,  
stored in a retrieval system, or transmitted, in any form or by any means,  
electronic, mechanical, photocopying, recording or otherwise, without  
the prior permission of the copyright owner.

ISBN (10): 1-5275-6618-8

ISBN (13): 978-1-5275-6618-7

# TABLE OF CONTENTS

|  |     |
|--|-----|
| Preface .....  | vii |
| Chapter 1 .....  | 1   |
| An Overview  |     |
| Chulananda Goonasekera, Emma-Jane Smith                                      |     |
| Chapter 2 .....  | 9   |
| Historical Aspects   |     |
| Priyanka Iyer  |     |
| Chapter 3 .....  | 26  |
| Neuro-Anatomy and Neurophysiology  |     |
| Natalie Simon, Hazel Sanghvi, Priya Sekhon, John Hanrahan,<br>Cristina Bleil |     |
| Chapter 4 .....  | 38  |
| Brain Mapping: Neurophysiologists' Perspective                               |     |
| Noemia Pereira, Hannah Keeble  |     |
| Chapter 5 .....  | 54  |
| Spinal Mapping: Neurophysiologists' Perspective                              |     |
| Pedro Coelho   |     |
| Chapter 6 .....  | 76  |
| Spinal Surgery: Surgeons' Perspective  |     |
| Daniel Ochieng   |     |
| Chapter 7 .....  | 85  |
| Awake Surgery: Anaesthetists' Perspective                                    |     |
| Holly Jones  |     |
| Chapter 8 .....  | 99  |
| Implications of General Anaesthesia  |     |
| Robin Kumar, Chulananda Goonasekera  |     |

|  |     |
|--|-----|
| Chapter 9 .....  | 114 |
| Depth of Anaesthesia Monitoring                        |     |
| Catalina Stendall, Sarah Nour                          |     |
| Chapter 10 .....                                       | 134 |
| Getting IONM Right in Children                         |     |
| Natasha Woodman, James Gill                            |     |
| Chapter 11 .....                                       | 148 |
| Pre-Operative Assessment                               |     |
| Emma-Jane Smith  |     |
| Chapter 12 .....                                       | 166 |
| Complications  |     |
| Sacha Salamon White, Aditi Nijhawan, Rebekah Lawrence, |     |
| Chulananda Goonasekera                                 |     |
| Chapter 13 .....                                       | 179 |
| The Patient Experience                                 |     |
| Rebekah Lawrence, Alina Amir                           |     |
| Chapter 14 .....                                       | 186 |
| What We Know and Where to Next                         |     |
| Chulananda Goonasekera, Pedro Coelho, Holly Jones,     |     |
| Christopher Chandler                                   |     |

## PREFACE

Modern intra-operative neurophysiological monitoring, or IONM, represents an enormous technological advance in modern neurosurgery. Its modalities are diverse and continually evolving, and there exists wide variability in its practice. Relatively few books have been written on the subject, and it can seem daunting and impenetrable to the uninitiated.

Recognising these hurdles, we set out to distil the expertise of our regional neurosciences centre into a collaborative multidisciplinary text. We hope that this practical guide will: serve as a foundation for the clinician new to IONM; promote mutual understanding and effective team working between the different disciplines involved in its application; and ultimately, enhance patient care.





# CHAPTER 1

## AN OVERVIEW

CHULANANDA GOONASEKERA

EMMA-JANE SMITH

### **What is intra-operative neurophysiological monitoring (IONM)?**

Unlike most human organs, neural structures such as the brain and spinal cord do not have the capacity to regenerate after an insult. Such damage – intrinsic or extrinsic – is therefore frequently associated with subsequent permanent disability. The major aetiologies of neurosurgical morbidity involve tumour invasion and neural tissue compression, which often require urgent intervention.

Neurosurgery is therefore focussed on preventing any further, or secondary, neural injury from a primary insult, in order to secure the best possible long-term outcomes for patients. Resection of brain tumours and correction of spinal lesions constitutes a large proportion of this work. Surgical intervention must be meticulous in order to minimise damage to normal structures, and yet the differentiation of the latter from abnormal tissue is highly challenging. To better facilitate this crucial process, various “static” techniques exist, mainly based on superimposed anatomical imaging or tissue staining. Intra-operative neurophysiological (or simply neuro-) monitoring (IONM) techniques offer a novel, “dynamic”, method for functional assessment of neural structures in real time.

In the 1930s, direct cortical stimulation was used to locate the motor cortex in patients with epilepsy (Penfield and Boldrey 1937). Decades later, more sophisticated IONM techniques began to emerge (Nuwer 2008), but it was not until the 1990s that one particular modality – transcranial motor evoked potentials (TcMEPs) – became an established method of monitoring corticospinal tract activity. Today, IONM has

become a dynamic aid in intra-operative decision-making and a primary tool for the prediction of neurological outcome (Kothbauer, Deletis, and Epstein 1997). It provides a real-time functional mapping technique to discriminate between normally functioning and dysfunctional structures in the anaesthetised patient. The method employs various electrodes to observe the spontaneous electrical activity of the brain and its reactions to stimuli. Multimodal IONM enables monitoring of a variety of neural structures including the cortex, brainstem, peripheral nerves, neuromuscular junction and spinal cord (Stecker 2012) (Kim et al. 2013). In practice, surgery involving “eloquent” cortex (areas in which damage is prone to cause major focal neurological deficits) may still require traditional Stagnara “wake-up” testing, in which anaesthesia is lightened intra-operatively and the patient asked to follow various commands in order to verify functional integrity (Vauzelle, Stagnara, and Jouvinroux 1973). However, the advent of IONM has successfully avoided this technique for many patients, especially children.

## **IONM in practice**

### **Electrode placement**

The placement of electrodes for IONM takes place after induction of general anaesthesia (NICE 2008). Corkscrew electrodes are attached to the surface of the scalp to monitor the spontaneous electrical activity of the brain. Needle electrodes may be implanted into the spine, limbs, tongue, eyes, ears, face or perineum to record evoked responses to various electrical stimuli (Legatt et al. 2016). The placement of these electrodes varies according to surgical field and neuromonitoring mode requirements. Mobile or dislodged electrodes may produce inaccurate results (Legatt et al. 2016) and so these must be secured with care.

### **Pre-surgical benefits**

Suboptimal patient positioning for surgery is known to risk both neurological and vascular compromise, which can impact on IONM, as well as causing significant postoperative morbidity. This is of particular concern when substantial cervical spine flexion is necessary for surgical access, such as in the sitting or prone positions. Baseline motor and somatosensory evoked potentials are therefore commonly performed in the supine position following induction of anaesthesia, and then repeated once positioning is complete. This permits adjustment of position should a deterioration in

recorded potentials be detected prior to the start of surgery – in other words, a deficit arising as a result of imperfect positioning alone. However, vigilance must be maintained as changes may also occur intra-operatively if minor changes in position have taken place, such as from muscular contractions elicited by IONM. Changes in, or loss of, signals can also occur as a result of artefact from misplaced electrodes, or electrical interference from muscle activity or surgical equipment.

## **Modalities**

There are numerous modalities of IONM. These are often used in combination during a single operation as each approach provides unique information (Kim et al. 2013); the use of a greater number of modalities also confers a higher margin of safety. A summary of the commonly used modalities is listed here.

### **Electro-encephalography (EEG) and Electrocorticography (ECoG)**

An EEG machine records brain electrical activity using corkscrew needles placed in the postcentral parietal regions of the scalp (Kim et al. 2013). EEG recordings, best known for their ability to detect seizure activity, also provide information on the depth of anaesthesia. ECoG refers to similar readings but with electrodes placed directly on the exposed surface of the brain. This is also known as intracranial electro-encephalography or iEEG.

### **Electromyography (EMG)**

EMG examines the activity of skeletal muscle fibres and may be either spontaneous or provoked (“triggered”). Needle electrodes are placed in certain muscle groups and electrical activity is recorded with or without concurrent electrical stimulation. The use of both spontaneous and triggered modes together leads to more effective anticipation and minimisation of damage to nerve roots (Lall et al. 2012).

### **Motor Evoked Potentials (MEPs)**

This is a form of transcranial electrical stimulation, also known as transcranial motor evoked potentials (TcMEPs). Electrodes on the scalp stimulate the primary motor cortex to examine the integrity of the descending corticospinal tracts. MEP monitoring contributes to deficit

prevention during the resection of tumours of the cerebral cortex and spinal cord, and is highly specific and sensitive in predicting postoperative neurological deficit (Rho, Rhim, and Kang 2016). It is also used to detect spinal cord ischaemia during thoracic aortic reconstruction.

### **Muscle Motor Evoked Potentials (mMEPs)**

These refer to the recording of muscle contractions generated from needle electrodes inserted directly into muscles. Both MEPs and mMEPs can only be assessed intermittently during surgery as they may cause significant patient movement. This necessarily interrupted assessment invites the risk of delay in identifying neurological damage.

### **Somatosensory Evoked Potentials (SSEPs)**

SSEPs are recordings of ascending sensory signals to monitor the dorsal column–medial lemniscus pathway (Lall et al. 2012). Stimulating electrodes are frequently placed over the median and ulnar nerves in the upper limb, and the posterior tibial nerve in the lower limb (Lall et al. 2012). Signals are recorded via electrodes placed on the scalp. Unlike MEPs, SSEPs can be continuously monitored during surgery.

### **Visual Evoked Potentials (VEPs)**

VEPs assess the visual pathway. A device that produces flashes of light is placed over each closed eyelid. The electrical potentials generated by these brief visual stimuli are recorded via scalp electrodes.

### **Brainstem Auditory Evoked Potentials (BAEPs)**

These potentials are generated by auditory stimulation of the vestibulocochlear nerve. This reduces the risk of damage to this cranial nerve during surgery involving its course, such as resection of acoustic neuromata (Kim et al. 2013).

### **Anaesthetic implications of IONM**

Although neuromonitoring confers attractive advantages, its accuracy is dependent on the fulfilment of multiple preconditions and major modifications to anaesthesia (Cabraja et al. 2009).

## **Physical conditions**

Signal recordings are vulnerable to changes in physical parameters such as body temperature, blood pressure and haemoglobin concentration, which the anaesthetist must strive to keep at optimal levels. The maintenance of stable conditions is particularly challenging during procedures involving significant blood loss or tissue irrigation.

## **Anaesthetic agents**

Many anaesthetic drugs impact on the use of IONM, with the effects being dependent on several variables including type of agent, dosage, and mode of neuromonitoring in question (Banoub, Tetzlaff, and Schubert 2003). Evoked responses which travel via polysynaptic pathways, such as VEPs, are significantly more susceptible to the vagaries of anaesthesia and surgical conditions when compared to pathways with fewer synapses (Soghomonyan et al. 2014).

Inhalational agents such as sevoflurane are commonly used for anaesthetic maintenance but are potent suppressants of evoked potentials, rendering many forms of IONM uninterpretable. Intravenous anaesthetic drugs confer much less interference, hence the popularity of total intravenous anaesthesia (TIVA) for maintenance of anaesthesia during IONM. TIVA is characterised by continuous intravenous infusions of anaesthetic drugs, typically the anaesthetic agent propofol in combination with the ultra-short-acting synthetic opiate remifentanyl. Administration is titrated to the individual patient according to clinical parameters and supplementary depth of anaesthesia (DOA) monitoring.

Neuromuscular blocking agents (NMBAs) also interfere with IONM. This is most apparent in EMG and MEP monitoring, as signal transmission across the neuromuscular junction is partially or totally impeded. Consequently, the use of these drugs is either restricted to induction of anaesthesia in order to facilitate endotracheal intubation (with preference given to shorter-acting agents), or avoided entirely (Kim et al. 2013).

## **Depth of anaesthesia monitoring**

Bispectral Index (BIS), E-Entropy and Narcotrend Compact M are all patented examples of DOA monitoring, with BIS being the most commonly encountered at the time of writing. All are primarily based on processed EEG signals and allow the dose of anaesthetic agent to be

tailored to the individual patient. This aims to reduce the risk of both underdosage (with an attendant risk of awareness under general anaesthesia (AAGA)), and overdosage (with its associated cardiovascular side effects and prolonged recovery from anaesthesia). The use of DOA monitoring is considered the standard of care during TIVA, and therefore most cases involving the use of IONM; however, it is not without limitations. BIS, for example, is based on information from just four electrodes, and is susceptible to inference from muscle activity and altered cerebral perfusion. Clinicians must be mindful of these shortcomings and assimilate the range of available clinical information to gain an accurate impression of anaesthetic depth.

### **Electrode placement**

Electrodes may be sited in areas of particular concern to the anaesthetist, including the vocal cords, soft palate, tongue and eye muscles. Such placement is typically necessary when cranial nerve monitoring is being undertaken, for example in brainstem or posterior fossa surgery. In addition to electrode location, the anaesthetist must also anticipate the muscular contractions that follow intermittent intra-operative stimulation: a soft “bite block” between the molar teeth helps to avoid intra-oral injury from jaw clenching, for example.

### **Adverse events**

IONM and the modifications to anaesthetic technique that it necessitates invite added risks, including AAGA, seizures, cardiac dysrhythmias, dental and oral damage and calf muscle injury; very rarely, severe injury such as bone fracture may occur. These risks are mitigated by DOA monitoring, bite blocks, careful positioning and most importantly, intra-operative vigilance.

### **The neuromonitoring team**

The combined knowledge and experience of the surgeon, anaesthetist, neurophysiologist and wider theatre staff is crucial to obtain meaningful and reliable IONM results (Kim et al. 2013). Communication between these specialist roles is imperative for the successful application of neuromonitoring, as is understanding of the surgical procedure, neurophysiology and the effects of general anaesthesia (Stecker 2012). The detection of IONM signal changes must be swiftly communicated to the

rest of the team to enable a coordinated response to prevent injury to the patient. IONM should be discussed at the presurgical team briefing and incorporated into local versions of the World Health Organisation (WHO) Surgical Safety Checklist.

## Ethics and research

Although the theoretical benefits of IONM are clear and its use continues to increase (Soghomonyan et al. 2014), information on its efficacy, complications and patient impact remains sparse. As a technique, it remains a prototype and continues to evolve (Rho, Rhim, and Kang 2016) (Sala 2010). There currently exists no uniform standard of care or evidence-based guideline for neuromonitoring across all centres, as the methods employed are diverse and developed based on the experience and understanding of local teams. Nonetheless, IONM is considered by many to be the gold standard for the intra-operative prevention of inadvertent neuronal injury (Coppola et al. 2016).

Current research investigating IONM is directed mainly towards exploring the physiology and efficacy of the technique (Cabraja et al. 2009), but studies are also needed to elucidate its influence on outcomes, associated postoperative morbidity and patient experience. The recurrence of tumours after neurosurgery guided by IONM, and the potential humoral effects of electrical stimulation on tumour behaviour, are other areas which remain as yet unexplored.

## References

- Banoub, M., J. E. Tetzlaff, and A. Schubert. 2003. "Pharmacologic and physiologic influences affecting sensory evoked potentials: implications for perioperative monitoring." *Anesthesiology* 99 (3):716-37.
- Cabraja, M., F. Stockhammer, S. Mularski, O. Suess, T. Kombos, and P. Vajkoczy. 2009. "Neurophysiological intraoperative monitoring in neurosurgery: aid or handicap? An international survey." *Neurosurgical Focus* 27 (4):E2.
- Coppola, A., V. Tramontano, F. Basaldella, C. Arcaro, G. Squintani, and F. Sala. 2016. "Intra-operative neurophysiological mapping and monitoring during brain tumour surgery in children: an update." *Childs Nervous System* 32 (10):1849-59.

- Kim, S. M., S. H. Kim, D. W. Seo, and K. W. Lee. 2013. "Intraoperative neurophysiologic monitoring: basic principles and recent update." *Journal of Korean Medical Science* 28 (9):1261-9.
- Kothbauer, K., V. Deletis, and F. J. Epstein. 1997. "Intraoperative spinal cord monitoring for intramedullary surgery: an essential adjunct." *Pediatric Neurosurgery* 26 (5):247-54.
- Lall, R. R., R. R. Lall, J. S. Hauptman, C. Munoz, G. R. Cybulski, T. Koski, A. Ganju, R. G. Fessler, and Z. A. Smith. 2012. "Intraoperative neurophysiological monitoring in spine surgery: indications, efficacy, and role of the preoperative checklist." *Neurosurgical Focus* 33 (5):E10.
- Legatt, A. D., R. G. Emerson, C. M. Epstein, D. B. MacDonald, V. Deletis, R. J. Bravo, and J. R. Lopez. 2016. "ACNS Guideline: Transcranial Electrical Stimulation Motor Evoked Potential Monitoring." *Journal of Clinical Neurophysiology* 33 (1):42-50.
- NICE. 2008. Intraoperative nerve monitoring during thyroid yroid surgery. edited by National Institute for Health and Care Excellence. Manchester: National Institute for Health and Care Excellence.
- Nuwer, M. R. 2008. "Intraoperative Monitoring of Neural Function." In *Handbook of Clinical Neurophysiology*, edited by Marc Newer, 1-955. New York: Elsevier Ltd.
- Penfield, W., and E. Boldrey. 1937. "Somatic motor and sensory representation in the cerebral cortex of man as studied by electrical stimulation." *Brain* 60 (4):389-443.
- Rho, Y. J., S. C. Rhim, and J. K. Kang. 2016. "Is intraoperative neurophysiological monitoring valuable predicting postoperative neurological recovery?" *Spinal Cord* 54 (12):1121-1126.
- Sala, F. 2010. "Intraoperative neurophysiology is here to stay." *Childs Nervous System* 26 (4):413-7.
- Soghomonyan, S., K. R. Moran, G. S. Sandhu, and S. D. Bergese. 2014. "Anesthesia and evoked responses in neurosurgery." *Frontiers in Pharmacology* 5:74.
- Stecker, M. M. 2012. "A review of intraoperative monitoring for spinal surgery." *Surgical neurology international* 3 (Suppl 3):S174-87.
- Vauzelle, C., P. Stagnara, and P. Jouvinroux. 1973. "Functional monitoring of spinal cord activity during spinal surgery." *Clinical Orthopaedics & Related Research* 93:173-8.



# CHAPTER 2

## HISTORICAL ASPECTS

### PRIYANKA IYER

#### **Introduction**

The need for a monitoring technique of the spinal cord arose alongside evolving surgical techniques, such as that of corrective surgery for severe scoliosis (Harrington 1962). Intra-operative neurophysiological monitoring (IONM) was born as a consequence, with the overarching aim of preventing neurological deficits following surgery. It is a mapping and monitoring technique which assesses the integrity of neuronal structures during brain and spinal surgery (Sala 2010), and has become a valuable method of intra-operative neurological assessment (Stecker 2012). The use of IONM nowadays frequently eliminates the need for conventional wake-up testing during neurosurgery, with the exception of procedures involving areas relating to more complex functions, such as speech.

This chapter highlights the major milestones and discoveries that have contributed to modern-day intra-operative monitoring of the motor and sensory tracts.

#### **Origins**

Hans Berger is credited with the invention of electro-encephalography (EEG) in the 1920s, with the alpha wave still occasionally bearing his name (“Berger wave”) (Penfield and Boldrey 1937). Electrical activity in muscle was first recorded by Du Bois-Reymond (Penfield and Boldrey 1937).

In 1935, intra-operative internal EEG (electrocorticography or ECoG) was used for locating the motor cortex in patients with epilepsy (Penfield and Boldrey 1937). The investigators published a complete analysis of the

records of 163 patients whose cortices they had electrically explored under local anaesthesia. The challenges of the rudimentary mapping procedure were significant, with the authors noting that it was “impossible to confine functional representation within strict cyto-architectural boundaries” (Penfield and Boldrey 1937). The authors highlighted the crucial role of the anaesthetist, who was required to follow the movements and behaviour of the patient, as well as monitor blood pressure, heart rate and other parameters. Neurostimulation was carried out by either unipolar or bipolar platinum electrodes with a thyratron stimulator, employing a wave frequency of 55-65 Hz.

Shortly after the debut of the EEG, somatosensory evoked potentials (SSEPs) were developed in the 1940s (Liem 2016). Despite these two significant initial advances, IONM as a technique then stagnated for several decades (Nuwer 2008). The first transcranial motor evoked potentials (TcMEPs) were recorded in 1980 (Merton and Morton 1980), but this only became an established method of monitoring corticospinal tract activity in the 1990s. This delay was mainly due to the available anaesthetic agents of the day significantly interfering with the evoked potentials produced. TcMEPs have since been used to monitor the functional aspects of not only the corticospinal motor tracts, but also spinal nerve roots, peripheral nerves, and nerve plexuses (Devlin and Schwartz 2007).

In conjunction with scientific developments, industry played an important role through advances in commercial multi-channel IONM equipment (Kim et al. 2018). Prior to the availability of such equipment, neurophysiologists frequently devised or modified their own.

The uptake of IONM across the world owes as much to advances in technology as it does to scientific endeavour. Currently the technique is increasing in usage and is recognised as the gold standard for the location and preservation of brain function during surgery (Sala 2010) (Coppola et al. 2016).

## **Monitoring the sensory pathways**

### **Spinal Cord Evoked Potentials (SCEPs): stimulation of the spinal cord**

American surgeon and polio specialist Jacquelin Perry was the first to highlight the need for intra-operative spinal cord monitoring (Tamaki and

Kubota 2007). A team led by Tamaki later began to investigate the feasibility of recording SSEPs during orthopaedic surgery. The research group visited the laboratory of Sidney Goldring at Washington University, whose research at the time was focused on the effects of anaesthesia on SSEPs (Kelly, Goldring, and O'Leary 1965). Tamaki discovered that the instruments involved were large and costly, and required electrical engineers to correctly operate them. In search of mitigation for these impracticalities, in 1972 Tamaki pioneered technology to enable direct stimulation of the spinal cord via the epidural space, producing a spinal cord evoked potential (SCEP), also known as a "D" wave (Kurokawa 1975). Potentials produced via these means were large in amplitude and could be easily recorded with basic electrical hardware in the operating theatre. An example of a SCEP is illustrated by Figure 2-1. The disadvantage to the technique was the need for invasive introduction of the stimulating and recording electrodes into the epidural and intrathecal spaces respectively – procedures which carried significant risks. An example of a modern epidural electrode is illustrated in Figure 2-2.

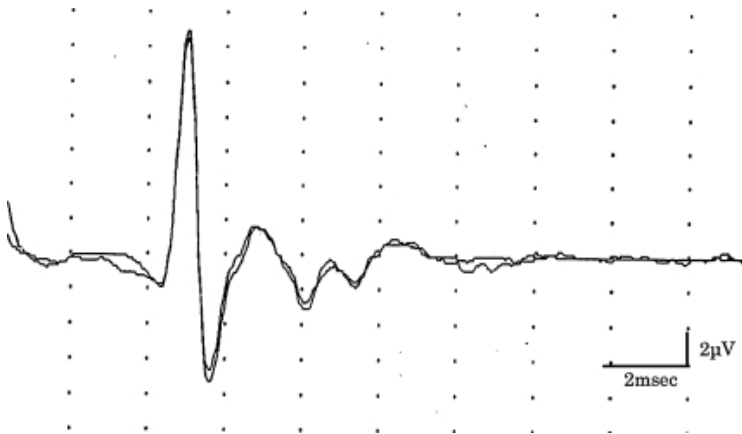


Fig. 2-1. A spinal cord evoked potential (SCEP) recorded at the level of T12 after stimulating the spinal cord at C7. The potential demonstrates an initial spike wave, followed by polyphasic waves. The summation of potentials from large diameter fibres in the posterolateral columns results in the initial high amplitude spike, with the subsequent smaller waves mainly reflecting dorsal column stimulation. Reproduced with permission (Tamaki and Kubota 2007).

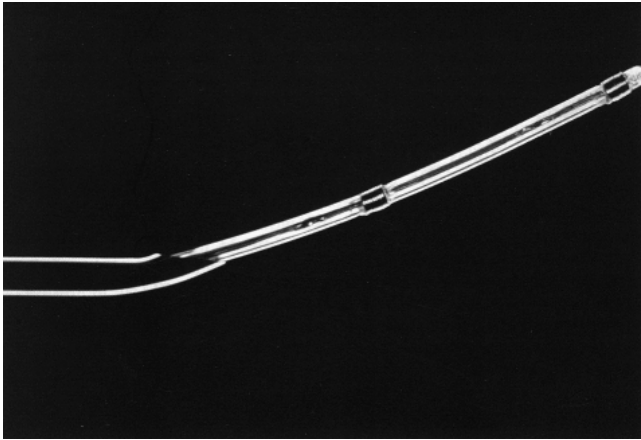


Fig. 2-2. A specially designed electrode comprising a flexible polyethylene tube with two coils of platinum wire, suitable for introduction into the epidural and intrathecal spaces. Reproduced with permission (Tamaki and Kubota 2007).

In essence, the SCEP represents a signal derived from both ascending and descending tracts passing close to a recording electrode. Unlike sensory potentials which are large in amplitude, motor potentials are more subtle, meaning that information from the descending tracts is more difficult to accurately record and interpret. False negative recordings – when neurological damage occurs insidiously and is not detected by signal changes – have been previously reported (Iwasaki et al. 2003). In a case series published by Koyanagi and colleagues, both false positive and false negative results were observed (Koyanagi et al. 1993). The authors' proposed reasons for these observations included inaccurate positioning of the stimulating electrode, differing thresholds in electrical stimulation of axons on the left and right sides of the spinal cord, and changes in distance between the electrode and spinal cord surface. It was therefore suggested that SCEP be used in combination with other types of evoked potentials to increase reliability.

### **Somatosensory Evoked Potential (SSEPs): stimulation of a peripheral nerve**

SSEP recordings are the most widely used modality in the spectrum of IONM. This non-invasive technique was initially introduced by Nash and colleagues in 1972, who demonstrated its use in patients undergoing scoliosis correction (Croft, Brodkey, and Nulsen 1972). The method

involves recording potentials by stimulating peripheral afferent nerves, with ascending impulses travelling through the dorsal column and culminating in the sensory cortex. The median nerve at the wrist is most frequently used for upper limb monitoring, whilst the lower limb equivalent is the posterior tibial nerve. Recording electrodes for both extremities are placed on the scalp (Figure 2-3). The slower-conducting spinothalamic pathway fibres are not monitored by this technique.

Later in the same decade, Nash reported a series of orthopaedic and neurosurgical patients in whom somatosensory cortical evoked potentials were used to monitor spinal cord integrity before, during and after their procedures (Nash et al. 1977). They concluded that the technique was effective, had few inherent risks in its application, and had the potential to greatly improve the safety of spine and spinal cord surgery.

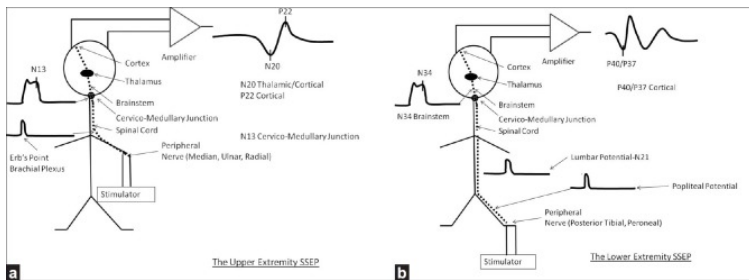


Fig. 2-3. Somatosensory evoked potential schematics from the upper and lower extremity. Reproduced with permission (Stecker 2012).

Interestingly, intra-operative SSEP monitoring during cervical spinal surgery can also provide important information on the functional integrity of brainstem structures, with the resultant ability to detect brainstem ischaemia. This was illustrated by a case report of a patient undergoing posterior cervical fusion with bilateral SSEP monitoring (Tran et al. 2012). During initial exposure of the C1 lamina, the SSEPs became asymmetrically reduced, and a postoperative MRI scan demonstrated bilateral posterior inferior cerebellar artery (PICA) territory infarcts. The asymmetry of SSEP change was consistent with medullary level impairment, permitting lateralisation of the vascular territory. Conversely, anterior spinal artery insults typically result in symmetrical deficits. Thus, interpretation of SSEPs demands a sound knowledge of medullary anatomy and vascular territories.

SSEPs are not without risk of false negative results, which have been seen in cases including infratentorial tumours presenting with brainstem compression, small lesions of the motor cortex, and small vessel damage during aneurysm surgery (Wiedemayer et al. 2004). The use of SSEPs as the sole modality of IONM is therefore not recommended as it relies heavily on the integrity of the dorsal columns alone.

Spinal somatosensory evoked potentials (spinal SSEPs) were introduced in the same decade as SSEPs (Shimoji, Higashi, and Kano 1971). They involve recording spinal electrograms from within the epidural space. As spinal SSEPs reflect the activity of the ascending dorsal column tracts, they can be extremely valuable during posterior myelotomy for the removal of intramedullary spinal cord tumours. This technique was taken up in particular by the Royal National Orthopaedic Hospital in Stanmore, UK, where results from 115 patients concluded that spinal SSEPs could effectively detect even minor spinal cord impairment, with reversible changes seen after surgical intervention (Jones et al. 1983). All signals were detected in response to posterior tibial nerve stimulation at the knee, with recording electrodes in the epidural space being placed cephalad to the area being fused. The epidural recording electrodes were noted to be simple to insert and unobtrusive to the operating surgeon.

### **The rationale for monitoring motor tracts**

Before the advent of directly testing the motor tracts during surgery, SSEP monitoring was used as an indirect measure. This technique relied on the anatomical proximity of the sensory and motor tracts, the premise being that pathology affecting the motor pathways would also manifest as disturbance in the sensory pathway, and the latter could be detected as a deterioration in the SSEP signal (Macdonald et al. 2013). Although SSEP monitoring was found to reduce the risk of paraplegia in spinal surgery by half (Nuwer et al. 1995), there have been cases noted in the literature where, despite unchanged intra-operative SSEPs, patients went on to demonstrate postoperative neurological deficits (Lesser et al. 1986). Possible explanations for this include: false negative results due to lesions outside the tract being assessed, for example motor deficits or below the level being monitored; pre-existing pathology that might render native tracts inaccessible to monitoring; technical problems that result in suboptimal recordings; and slowly progressive structural change either not immediately detectable, or detectable but irreversible in nature. As anaesthetic agents alone can affect the latency of the evoked potentials

intra-operatively, the authors stressed the importance of pre-set criteria which define an abnormality in signal.

## **Motor tract monitoring**

The historical milestones leading to modern-day IONM are summarised in Figure 2-4. The observation by Fritsch and Hitzig in 1870 that directly stimulating the frontal cortex of dogs can produce contralateral movement was one of the earliest recorded instances of motor evoked potential (MEP) monitoring (Fritsch and Hitzig 2009). The implementation of this technique in humans during brain surgery was pioneered by Horsley and Foerster (Macdonald et al. 2013).

Beginning in 1886, Victor Horsley performed operations on patients that involved electrical stimulation of the cortex (Tan and Black 2002). His first three craniotomy patients at Queen Square, London had intractable seizures secondary to lesions such as cortical scars, tumours or cysts within or near the motor cortex, and therefore were expected to respond favourably to localised excision. At the time, resection of such cortical “motor points” was hailed as a promising treatment for focal seizures.

Several years later, highly-trained neurologist and self-taught neurosurgeon Ofrid Foerster began his career by operating on peripheral nerves during the First World War. Many of his early patients were war veterans with intractable posttraumatic epilepsy (Uematsu, Lesser, and Gordon 1992). Alongside local anaesthesia to facilitate cortical mapping, Foerster used unipolar galvanic stimulation to induce clinical seizures, permitting localisation and then excision of the responsible focus. By 1931, having gathered information on more than 150 cases of cerebral cortical stimulation, Foerster’s experience surpassed that of any other neurosurgeon at the time.

A more advanced method known as the Penfield technique was later established by Penfield and Jasper, who routinely used direct cortical stimulation using a probe with 50-60 Hz pulse trains during epilepsy surgery (Penfield and Boldrey 1937) (Jasper 1952) (Jasper 1949). This was used as a surrogate test for cortical function, but the technique was only possible with local (as opposed to general) anaesthesia, hindering its widespread use. Soon after this, other methods of intra-operatively assessing cortical function and epileptic foci were trialled, including electrocorticography, electromyography, and nerve conduction studies (Walker, Johnson, and Marshall 1949).

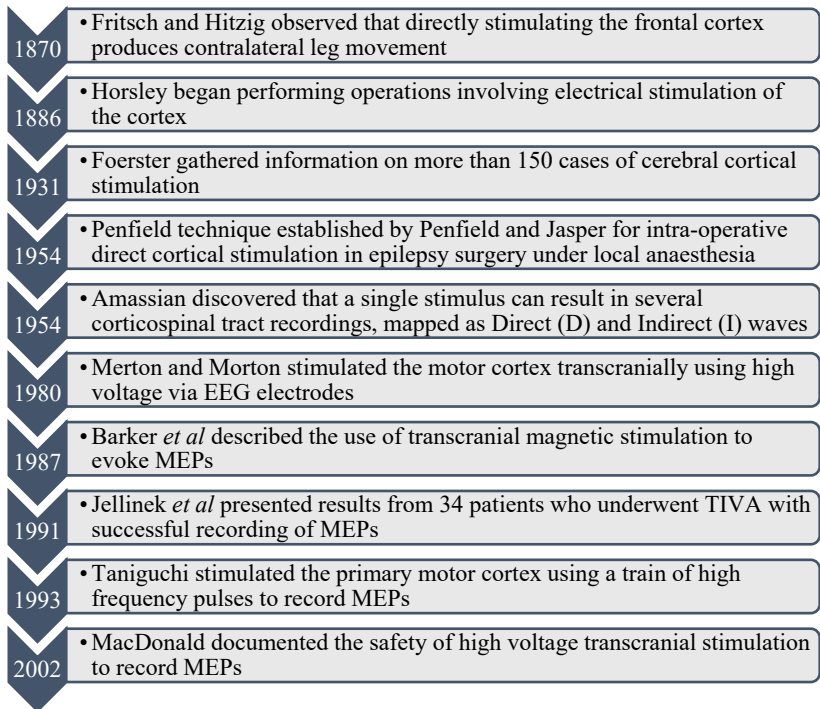


Fig. 2-4. Historical milestones in the development of motor tract monitoring.

The discovery by Amassian in 1954 that a single stimulus can result in several corticospinal tract signals which can be successfully mapped as a direct (“D”) and indirect (“I”) waves was the next milestone in the development of MEPs (Patton and Amassian 1954). D waves were represented by negative peaks – assumed to be represent direct activation of the corticospinal fibres – whilst I waves reflected high frequency repetitive discharges from the corticospinal tract (Figure 2-5).



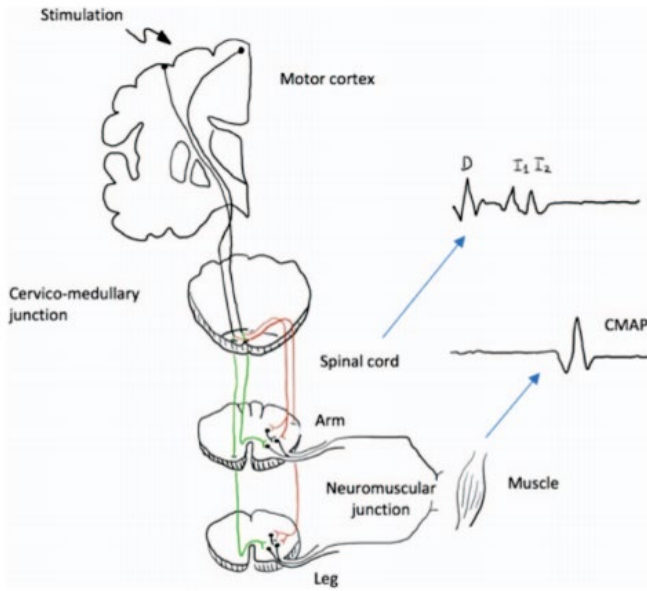


Fig. 2-5. Motor pathway monitored by motor evoked potentials, with the waveform recorded from both cord level (D and I waves) and muscle level (compound muscle action potentials). The red (right-hand) pathway reflects the majority of the motor fibres that reside in the lateral corticospinal tract after decussation at the brainstem level. The green (left-hand) pathway depicts the anterior corticospinal tract with fewer motor tracts. Reproduced with permission (Wing-hay and Chun-kwong 2019).

In 1980, Merton and Morton described stimulation of the motor cortex transcranially using a high voltage condenser ( $0.1 \mu\text{F}$ , charged to up to 2000 V) (Merton and Morton 1980). Electrodes placed on the scalp stimulated the primary motor cortex, thereby assessing the functional integrity of the descending corticospinal tracts (Figure 2-6). This technique successfully recorded evoked muscle action potentials. A major obstacle to its use in surgery was that the anaesthetic agents of the time – predominantly nitrous oxide and halogenated gases – inherently depressed motor neurone activity.

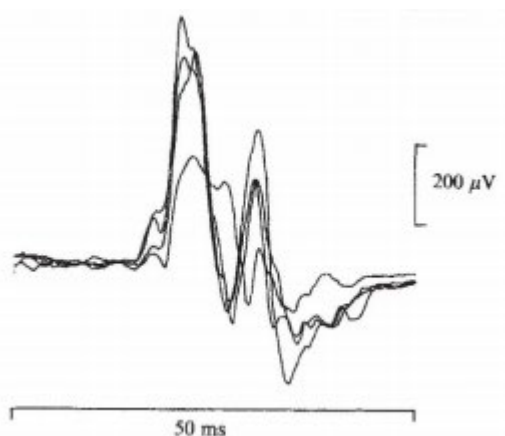


Fig. 2-6. Stimulation of the arm area of the motor cortex. These recordings represent the action potentials from the contracting muscles in the forearm. Reproduced with permission (Merton and Morton 1980).

In the same decade, a group of orthopaedic surgeons involved in corrective surgery for scoliosis recorded potentials from the scalp and spine after stimulation of the tibial nerve or the spinal cord in sixty patients. Similarly to cortical stimulation for MEPs, they found that recording meaningful muscle MEPs was difficult under general anaesthesia (Machida et al. 1985).

Boyd *et al* reported a case series of patients in whom high voltage stimulation (maximum output of 700 V, with a peak current of approximately 500 mA) was applied to the scalp over the motor cortex, with evoked motor potentials then being recorded by electrodes in the epidural space (Boyd et al. 1986). The authors described the technique as a useful adjunct to conventional sensory monitoring pathways, although placement of epidural electrodes was invasive with inherent risk, and the monitoring excluded lower motor neurones.

Similarly, Barker and colleagues described the use of transcranial magnetic stimulation to evoke MEPs, but again this could not be employed under general anaesthesia (Barker, Jalinous, and Freeston 1985). Paired cortical stimuli were introduced by others (Inghilleri et al. 1990) (Taylor et al. 1993) to overcome this problem, employing the principle of effective accumulation of excitatory post-synaptic potentials at the anterior horn motor neurones.

The introduction of total intravenous anaesthesia (TIVA) with agents such as fentanyl and propofol was a seminal event which finally rendered motor tract monitoring in the operating theatre feasible. Jellinek and colleagues presented results from 34 spinal surgery patients who underwent TIVA with propofol (Jellinek, Jewkes, and Symon 1991). Intra-operative monitoring of motor function with MEPs was successful in 88.5% of controls with normal pre-operative motor conduction; propofol was noted to cause a reduction in response amplitude of just 7% from baseline. Successful intra-operative monitoring was established in 87% of patients in the group with pre-existing abnormal neurology. Significant changes in both amplitude (greater than 50%) and/or onset latency (greater than 3 ms) were found within minutes of surgical manoeuvres, with three of the patients subsequently improving and a deterioration in motor function noted in two.

As already mentioned, a major hurdle in successfully measuring MEPs was to develop a technique that remained effective after the patient was anaesthetised. Taniguchi and colleagues first demonstrated a modification of the direct cortical stimulation technique that allowed MEPs to be recorded under general anaesthesia (Taniguchi, Cedzich, and Schramm 1993). Instead of the traditional method of applying a train of lower frequency impulses of the order of 50-60 Hz, the investigators stimulated the exposed primary motor cortex with a brief trains of high frequency pulses (300-500 Hz), with compound muscle action potentials (CMAPs) being recorded from the forearm and hand muscles. Their hypothesis was that this stimulation resulted in repetitive activation of the descending motor tract; it was found that surgical manipulation then demonstrably affected the motor pathways and the resultant MEPs.

Jones and colleagues were one of three groups that successfully demonstrated MEPs under anaesthesia in response to transcranial electrical stimulation (Jones et al. 1996). They monitored 22 patients anaesthetised with propofol, with or without nitrous oxide. Responses were consistently measurable in every patient but one, and the investigators concluded that the technique was especially useful in patients with myelopathy in the thoracic region. Pechstein *et al* found that instead of single pulse transcranial stimulation, high frequency repetitive electrical stimulation could evoke myogenic MEPs that recordable in forearm flexors, thenar and hypothenar muscles (Pechstein et al. 1996).

Development of electrical hardware in the form of a high-voltage transcranial stimulator manufactured by Digitimer Ltd enabled the

widespread use of motor tract monitoring. Its clinical safety was documented by MacDonald, who compared the safety of transcranial MEP monitoring with that of other brain stimulation methods in over 15,000 cases and found few adverse neuropsychological events (MacDonald 2002). This review concluded that the benefits of this modality outweighed the risks when applied to carefully selected patients under expert supervision.

Currently, electrical or magnetic stimulation of the motor cortex is used to obtain recordings of action potentials: either in the distal spinal cord or peripheral nerves as neurogenic potentials, or in muscle as myogenic potentials. Stimulating the brain electrically, either through electrodes on the scalp or directly on the cerebral surface, produces a current within the motor cortex which progresses primarily through the lateral corticospinal tract. Alternative methods include applying a pulsed magnetic field over the scalp.

## **Other IONM adjuncts**

### **Brainstem Auditory Evoked Potentials (BAEPs)**

Stimulation of the vestibulocochlear nerve by auditory stimuli to generate brainstem auditory evoked potentials (BAEPs) was introduced in 1982. BAEPs and EMG were later integrated into IONM with the aim of minimising the risk of damage to the eighth cranial nerve, which is particularly at risk during the surgical management of infratentorial lesions. Moller and colleagues reported data from 143 cases of microvascular decompression of the facial nerve for the surgical management of hemifacial spasm (Moller and Moller 1985). Due to the anatomical proximity of the vestibulocochlear nerve, a proportion of patients also underwent direct monitoring of auditory compound action potentials. Of all the cases, four patients reported profound hearing loss postoperatively, three of whom had not received intra-operative auditory monitoring. The fourth patient lost his hearing despite having been monitored. The reliability of BAEPs have therefore been questioned, with technical difficulties arising from detection of the potentials themselves.

### **Visual Evoked Potentials (VEPs)**

Adrian and Mathews were one of the first to successfully record visual evoked potentials (VEPs) (Adrian 1936) (Adrian 1937). By exposing eyes to flickering light and placing electrodes on the scalp, they were able to

record rhythmic potentials at a frequency of up to 25 Hz. By the 1960s, VEPs were starting to become an established neurophysiological test, with their utility being explored as a diagnostic tool for demyelinating disease, tumours compressing the optic pathway, and stroke, amongst other pathologies. It was only a decade later that the technique was employed intra-operatively as a surrogate for the integrity of the visual pathway, particularly for orbital, transsphenoidal, cortical and endoscopic surgery (Sharika, Mirela, and Dinesh 2016) (Anschel 2018) (Singh 2018).

## Conclusion

Real-time monitoring of the neural tracts with IONM is invaluable in preventing neurological deficits after surgery, thereby transforming patient outcomes. This chapter has explored the origins of the technique, including major milestones achieved in the monitoring of sensory and motor tracts and other pathways. The unwanted effects of volatile anaesthetic agents on spontaneous and evoked potentials, and the lack of specific equipment, were major obstacles that had to be overcome before the technique could gain traction around the world. The utility of IONM continues to evolve based on the accumulated experience and understanding of surgeons, anaesthetists and neurophysiologists.

## References

- Adrian, E. D. 1937. "Synchronized reactions in the optic ganglion of dytiscus." *Journal of Physiology* 91 (1):66-89.
- Anschel, D. J. 2018. "Intraoperative Visual Evoked Potentials." *Journal of Clinical Neurophysiology* 35 (4):355.
- Barker, A. T., R. Jalinous, and I. L. Freeston. 1985. "Non-invasive magnetic stimulation of human motor cortex." *Lancet* 1 (8437):1106-7.
- Boyd, S. G., J. C. Rothwell, J. M. Cowan, P. J. Webb, T. Morley, P. Asselman, and C. D. Marsden. 1986. "A method of monitoring function in corticospinal pathways during scoliosis surgery with a note on motor conduction velocities." *Journal of Neurology, Neurosurgery & Psychiatry* 49 (3):251-7.
- Coppola, A., V. Tramontano, F. Basaldella, C. Arcaro, G. Squintani, and F. Sala. 2016. "Intra-operative neurophysiological mapping and monitoring during brain tumour surgery in children: an update." *Childs Nervous System* 32 (10):1849-59.

- Croft, T. J., J. S. Brodkey, and F. E. Nulsen. 1972. "Reversible spinal cord trauma: a model for electrical monitoring of spinal cord function." *Journal of Neurosurgery* 36 (4):402-6.
- Devlin, V. J., and D. M. Schwartz. 2007. "Intraoperative neurophysiologic monitoring during spinal surgery." *Journal of the American Academy of Orthopaedic Surgeons* 15 (9):549-60.
- Fritsch, G., and E. Hitzig. 2009. "Electric excitability of the cerebrum (Uber die elektrische Erregbarkeit des Grosshirns)." *Epilepsy & Behavior* 15 (2):123-30.
- Harrington, P.R. 1962. "Treatment of Scoliosis." *The Journal of Bone and Joint Surgery* 44-A (4):591-634.
- Inghilleri, M., A. Berardelli, G. Cruccu, A. Priori, and M. Manfredi. 1990. "Motor potentials evoked by paired cortical stimuli." *Electroencephalography & Clinical Neurophysiology* 77 (5):382-9.
- Iwasaki, H., T. Tamaki, M. Yoshida, M. Ando, H. Yamada, S. Tsutsui, and M. Takami. 2003. "Efficacy and limitations of current methods of intraoperative spinal cord monitoring." *Journal of Orthopaedic Science* 8 (5):635-42.
- Jasper, H. H. 1949. "[The electroencephalography in neuro-surgery]." *Presse Medicale* 57 (63):890.
- Jasper, H. H. 1952. "Electroencephalography." *Pediatrics* 9 (6):786-7.
- Jellinek, D., D. Jewkes, and L. Symon. 1991. "Noninvasive intraoperative monitoring of motor evoked potentials under propofol anesthesia: effects of spinal surgery on the amplitude and latency of motor evoked potentials." *Neurosurgery* 29 (4):551-7.
- Jones, S. J., M. A. Edgar, A. O. Ransford, and N. P. Thomas. 1983. "A system for the electrophysiological monitoring of the spinal cord during operations for scoliosis." *Journal of Bone & Joint Surgery - British Volume* 65 (2):134-9.
- Jones, S. J., R. Harrison, K. F. Koh, N. Mendoza, and H. A. Crockard. 1996. "Motor evoked potential monitoring during spinal surgery: responses of distal limb muscles to transcranial cortical stimulation with pulse trains." *Electroencephalography & Clinical Neurophysiology* 100 (5):375-83.
- Kelly, D. L., Jr., S. Goldring, and J. L. O'Leary. 1965. "Averaged Evoked Somatosensory Responses from Exposed Cortex of Man." *Archives of Neurology* 13:1-9.
- Kim, K., C. Cho, M. S. Bang, H. I. Shin, J. H. Phi, and S. K. Kim. 2018. "Intraoperative Neurophysiological Monitoring: A Review of Techniques Used for Brain Tumor Surgery in Children." *Journal of Korean Neurosurgical Society* 61 (3):363-375.